

ORIGINAL ARTICLE

# The 2-Day Light Phenol Chemabrasion for Deep Wrinkles and Acne Scars: A Presentation of Dace and Neck Peels

Peter Paul Rullan, MD; Janet Lemon, RN; Jennifer Rullan, BS

**Introduction:** Most physicians associate the term phenol peel with the Baker-Gordon formula and have not kept up with the resurgence of modified, light phenol peels that were popularized by lay peelers since the 1920s. Deep dynamic rhytides and acne scars are typically resistant to current resurfacing techniques. The concepts of reapplying phenol on abraded skin and phenol neck peeling are neither well understood nor accepted.

**Materials and Methods:** Seventy-eight patients were treated and followed over 3 years, with various formulations of modified light phenol formulas. High-quality before and after photographs were taken, documenting the results. Patients were separated into 3 categories: acne scars, aging, and those with both. Neck peels were done on 19 patients. Full cardiac monitoring was performed and assessed. A telephone survey and a blinded-observers evaluation of the before and after photographs was done to assess the satisfaction index, color changes, and incidence of scars. A paired comparison to evaluate the need for chemabrasion versus peel alone for the treatment of acne scars was performed. A histologic study to evaluate the depth of injury and inflammation, to compare phenol alone versus chemabrasion was done.

**Results:** Forty-four percent of the patients had Skin Photo Types II–IV. The use of epinephrine for nerve blocks during the initial 30 cases was associated with 1 case of asymptomatic PVCs and 4 PACs during eyelid application. The last 48 patients had no epinephrine, and there were no further arrhythmias. Photographic evaluation showed that acne scars improved 80%, wrinkles improved 90%, and those with both conditions improved 86%. There were no

facial scars and no cases of depigmentation over a 2-year follow-up. Four neck peels developed small scars that resolved completely with treatment. The paired comparison showed that chemabrasion was superior to peeling alone for scar correction. Histologic studies showed that both Exoderm-Lift and Stone 2 wounded equally and that the second-day reapplication of these formulas did not cause a deeper injury. All patients were 100% re-epithelialized by day 8–9. Forty percent of patients had 10-minute spot touch-ups.

**Discussion:** The 2-day light phenol chemabrasion (PCA) is a very predictable peel without the associated complications seen with Baker-Gordon peels. Premixed, stable light phenol formulas are commercially available. This avoids the variability of mixing one's own formula and facilitates the teaching of this procedure as a well-defined and reproducible resurfacing technique. The 2-day PCA has the potential of becoming the treatment of choice for deep scar and wrinkle resurfacing.

## Introduction

Modified light phenol formulas with croton oil (CO) in the range of 0.1–0.7% were popularized by lay peelers in the 1920s through the 1990s. Early plastic surgeons, like Brown<sup>1</sup> and Litton,<sup>2</sup> used these formulas and these were analyzed in detail over the last few years by Hetter<sup>3–6</sup> and Stone.<sup>7,8</sup> The Baker-Gordon (BG) formula has 2.1% CO.<sup>1</sup> Baker himself modified these lay peelers' formulas. The BG has 3–20-fold higher concentration of CO.

The lead author's 20 years of peeling experience has led him to several observations and theories. Phenol peels can liquefy both the epidermis and upper dermis. This allows a more effective and easy abrasion of the edges and shoulders of deep scars and wrinkles,

Received for publication February 25, 2004.

From private practice at the Dermatology Institute (Dr Rullan, Ms Lemon), Chula Vista, Calif; Ms Rullan is a third-year medical student at University of California, Los Angeles.

Corresponding author: Peter Paul Rullan, MD, Dermatology Institute, 256 Landis Avenue, Chula Vista, CA 91910 (e-mail: prullan@yahoo.com).

**Concentrations of Peel Solution Components**

	Croton Oil (%)	Phenol (%)
Baker-Gordon	2.1	50
Fintsi	0.6–0.7	64
Stone-2	0.2	60
Stone V-K	0.16	62
Hetter	0.7	50
Hetter “all-around”	0.4	35
Hetter neck/eyelid	0.1	30

resulting in new collagen formation in these difficult-to-reach areas. Alternatively, trichloroacetic acid (TCA) causes protein denaturation without liquefaction. Carbon dioxide laser energy has water as its target, and after several passes, the tissue is desiccated and cannot be ablated more deeply no matter how many passes are done. This limits its effectiveness on deep scars and wrinkles. This limitation is compensated by combining carbon dioxide with erbium-YAG laser energy and is currently considered the gold standard. Dermabrasion is typically performed on tumesced skin in a bloody field, and separating normal versus scarred skin during dermabrasion requires a skilled operator.<sup>9</sup> The lead author's dissatisfaction with carbon dioxide laser resurfacing even with dermabrasion, as Fulton<sup>10</sup> has described, and the complication profile of the BG peel, prompted him to search further into the world of modified phenol peels. Further research led to Fintsi's chemabrasion technique,<sup>11</sup> where phenol is re-applied on abraded skin, a concept not easily accepted among experienced chemical peelers.

### Materials and Methods

We used several phenol formulas (Table), including the BG, Hetter's formulas,<sup>6</sup> as well as 2 commercially available modified phenol peels that had stable shelf lives. These included the Exoderm-Lift, which contains 12 ingredients,<sup>12</sup> including water, alcohol, olive oil, glycerin, sesame oil, resorcin, soap, citric acid, tris buffer, CO (0.6–0.7%), and phenol (64%). It sells for \$400/3-mL vial, sufficient to complete only 1 peel. We also used Stone's reformulations of lay peelers' formulas<sup>7</sup> that were purchased commercially (Delasco, Council Bluffs, Ia). The Stone 2 peel (purchased as Stone 100), made from the Grade 2 formula, contains 0.2% CO, 60% phenol in a water, glycerin, and olive oil solution, with a pH of 3.5. The Stone-Venner Kellson formula (purchased as Stone V-K) has a 0.16% CO, 62% phenol in a water, olive oil, and sepiisol solution,

with a pH of 7.0. The CO concentration in these formulas is less than 1/10 the strength of Baker-Gordon's (CO 2.1%, phenol 50%). Hetter's all-around formula<sup>6</sup> has 0.4% CO and 35% phenol, and his neck and eyelid formula has 0.1% CO and 30% phenol (in a sepiisol/water mixture).

Our study involved 78 patients, 63 females (81%) and 15 males (19%), with an age range from 17 to 84 years, with the younger set being treated for acne scars, the middle-age group for both acne scars and wrinkles, and the older set for wrinkles. All were peeled using a modified phenol formula, including 2 with Hetter's (0.7% CO and phenol 50%), 15 with Stone 2, 10 with a combination of Stone V-K followed by Stone 2, and 51 with Exoderm. Seventy of these were peeled using the 2-day PCA technique and 8 with the 1-day open-technique (one with Hetter, 7 with Stone 2). Nineteen female patients (24%) also had neck peels, 2 with Hetter (0.1% CO, phenol 30%), 15 with Stone 2, and 2 with Stone V-K. All 15 males were treated for acne scars. Of the 63 female patients, 46 were treated for wrinkles, 9 for acne scars, and 8 for both wrinkles and scars. Forty percent of patients had at least one regional touch-up, with acne-scar patients accounting for 80% of the touch-ups. The racial mix of patients was diverse, with 44% photo-type II–IV and 75% of them being Hispanic.

### Pre-Op

The 2-day PCA begins with the right patient selection, making sure they are healthy (assess for cardiac arrhythmia risk and renal and hepatic function for normal phenol clearance). Patients have to be off the drug isotretinoin for more than 6 months. Ideal candidates are those who need skin quality improvement and not just lifting. Skin phototype can be I–IV. They should meet ASA criteria for conscious sedation at an AAHC (or similar) certified facility, and you should work with either an anesthesiologist or a nurse anesthetist, as our center uses. The patient needs to have adequate family support, and 1 member of the family or a friend has to be trained as an assistant, including reviewing detailed pre- and postpeel instructions and watching a video. This avoids having to put patients in a recovery center. The patient is prepared to take a liquid diet (from a squeeze bottle) for 8 days following the procedure and instructed that there is to be no talking for 7 days. Oral medication prescriptions, including valacyclovir 1 gm/d for 10 days; ciprofloxin or cephalexin 500 mg BID for 7 days; diazepam 10 mg q6h prn; ketorolac tromethamine 10 mg q 6–8h for 5

days; trimethobenzamide 250 mg TID prn; hydro-morphone 2 mg q4h prn; and triazolam 0.25 mg qHS prn, are filled preoperatively. The usual skin preparation includes standard antiaging creams and hydroquinone if phototype III or IV. Quality digital photographs were taken using a 5-megapixel macrolens Fuji digital camera, a Sony Mavica, or a Canon Power-Shot with 3.2 megapixels. These are essential for setting realistic expectations and for reviewing the results afterward. The procedures are scheduled for 2 hours on the first day and 1 hour for the second day.

### *Operative Details*

Markings are placed 2 cm below the mandibular margin for all full-face peels or down to the sternal notch and around to the nape of the neck if doing a neck peel also. Intramuscular ketorolac tromethamine, 30 mg, and triamcinolone acetonide, 20 mg, are given intramuscularly to all patients 30 minutes before the peels. Automatic cardiac and pO<sub>2</sub> monitors are connected and an IV with Ringer lactate is started that will administer 1.0 L over 1 hour. Oxygen at 2L/min is delivered through nasal prongs. The patient receives fentanyl citrate 25–50 µg and 2 mg midazolam intravenously (IV) in incremental doses until we notice a calming effect. At that point, we begin with nerve blocks using first a buffered mixture of plain lidocaine 1% (without epinephrine) with 8.4% sodium bicarbonate, using 30-gauge, 1-inch needles. We immediately change syringes and then reinject the same site with a 50:50 dilution of 1% plain lidocaine and bupivacaine. We use approximately 12 mL of lidocaine-bicarb and 6 mL of lidocaine-bupivacaine. We do nerve blocks of the supraorbital, infraorbital, mental, supratrochlear, palatine, buccal, and branches of the cervical nerves and field blocks of the buccal, preauricular, lateral canthal, lower malar, and submental regions.

### *The Peel*

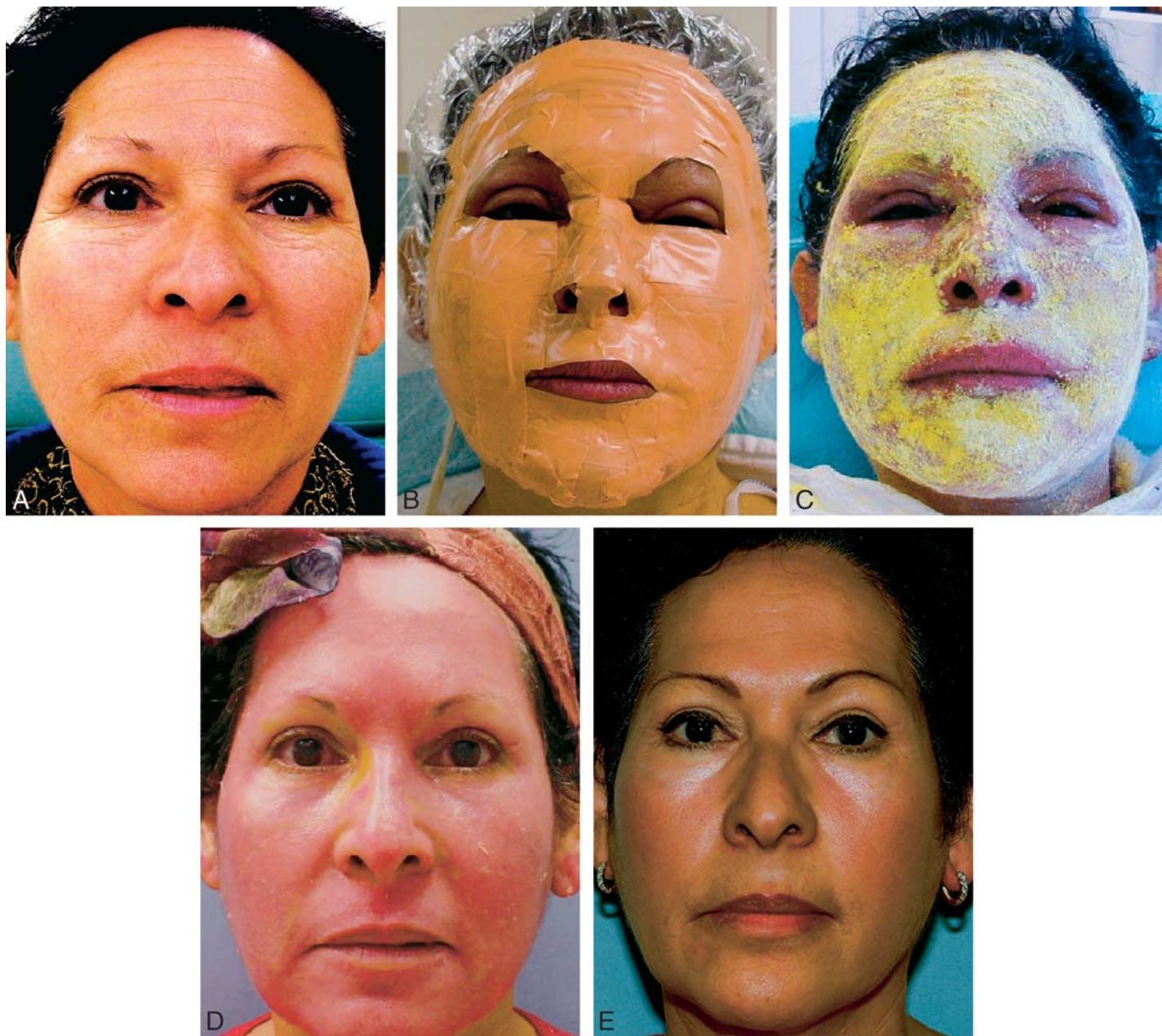
The skin is degreased (especially the hairline) with 5–6 cycles of alcohol and acetone and occasionally using Septisol. About 3 mL of well-shaken peel mixture is poured into a stainless-steel cup. Cotton-tipped applicators of various sizes are prepared, including large-tipped rectal swabs and pencil-tip Q-Tips. The applicator is dipped into the cup and then rolled against the wall until there is no dripping. The face is divided into 4 regions, each to be peeled sequentially, allowing 15 minutes per segment. These segments include the forehead and temples; each cheek down to the submandibular demarcation line and earlobes; and the

centrofacial region, including the upper and lower eyelids up to their ciliary margins. The solution is spread evenly and quickly until the region is completely and evenly frosted. Each region receives 2 applications (using the rectal swabs) of the phenol formulas during its 15 allotted minutes. Once the full face is completed, then the solution is applied into individual scars and deepest wrinkles, using a thin-tipped applicator. The assistant pulls the scar or wrinkle apart to allow the applicator to reach those deeper edges; this is done until a frost appears. For the entire process, 3 mL or less of peel solution is used. At the end of the peel, the skin appears edematous and firm, with a yellowish tinge suggestive of epidermolysis.

For neck peels, we used either Hetter 0.1% CO, Stone V-K, or Stone 2, wetting a 2 × 2 gauze, wringing it dry, and then wiping it with single strokes (thus minimizing overlap) to the entire neck from the nape and posterior hairline down to the sternal notch. The targeted endpoint is the appearance of light frosting or erythema. The solution is reapplied to areas where this endpoint has not occurred. Care is taken to avoid overapplication, which would be indicated by a heavier frost in the lower anterolateral region of the neck, where scarring is more likely. The neck is never taped and is never retreated on day 2.

A shower cap is placed on the scalp, to which the first tapes on the forehead are secured. The entire face, down to the 2-cm submandibular mark, is taped with 1- or 2-inch strips of HyTape (HyTape International, Patterson, NY), with a slight overlap, excluding the upper eyelids. Care is taken not to tape eyelashes (Figure 1A). Surgi- 13  
net mesh is placed over the face and taped down (Figure 1B). The patient is discharged once standard ASA criteria are met. The IV line is secured overnight with tape and a heparin lock. We maintain close contact with the patient's trained assistant.

The next day, the shower cap and the tape mask are removed, with IV conscious sedation, revealing a full-face coagulum that is then debrided with tongue depressors and gauze. Resistant areas still with epidermis are curetted as much as possible. The neck is never debrided except for breaking blisters. We then abrade the facial acne scars and wrinkles with curettes of different diameters or sand paper, the goal being to achieve punctate bleeding in the shoulders and deepest edges of these defects (Figure 2A). Because the tissue is soft and liquefied, the scars are easily abraded. Then the phenol solution is again applied with pencil-tip applicators into these deep edges and then over the regional area (Figure 2B). The solution is also applied

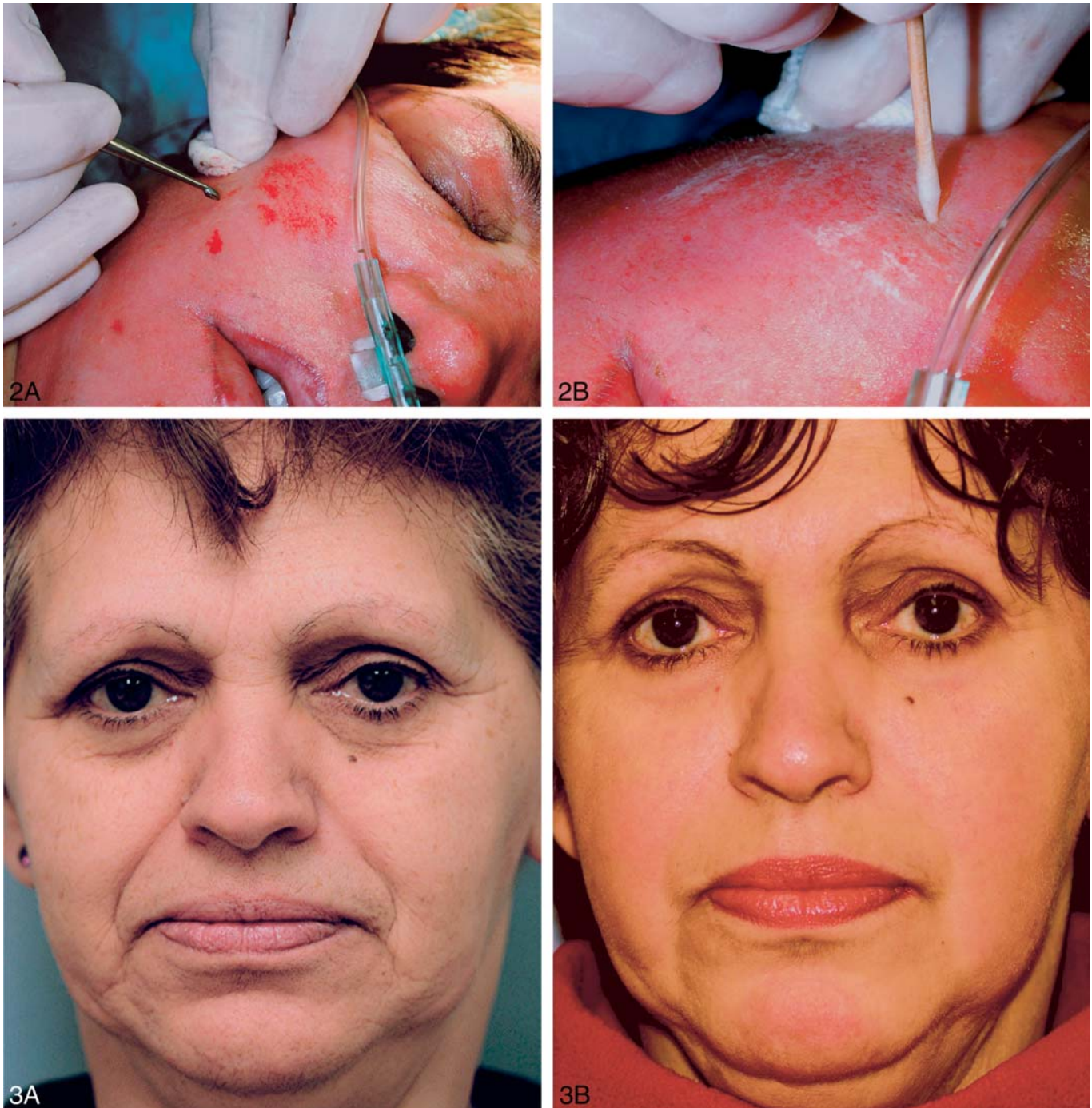

**Figure 1.** (A) Preoperative Latina patient, age ??, SPT IV, with wrinkles. (B) HyTape occlusive mask applied for 24 hours. (C) Bismuth subgallate powder applied for 6–7 days following mask. (D) 100% re-epithelialized skin consistent and predictable on day 8 or 9. (E) Two-year follow-up showing no dyschromia and persistent correction.

to regions where deep wrinkles or scars are located, using medium-sized Q-Tips. Yellow-green colored bismuth subgallate powder (Spectrum Chemical Corp. Gardena, Calif; also available thru Delasco) is applied with a brush to the entire face until a thick layer of it completely covers the face except for the upper eyelids (Figure 1C). This powder functions as an anti-inflammatory and antiseptic agent. This powder crust greatly speeds healing and reduces the time the crust is

in place. The powder crust hardens over the next 7 days. There is no need to reapply the powder at home unless some of it wipes off accidentally (the patient is sent home with extra powder).

The neck area (if it was peeled) is nursed with wet compresses of dilute vinegar soaks (1 teaspoon of white vinegar in 1 cup of cool tap water) and Aquaphor Healing Ointment (Beiesdorf, Hamburg, Germany). The compresses are repeated throughout the day in



**Figure 2.** (A) Curette-abrasion of scars or wrinkles to achieve punctate bleeding, on day 2 (could also use sandpaper). (B) Application of phenol on day 2 into deep scars or wrinkles.

**Figure 3.** (A) Preoperative patient, age 60, peeled with Stone 2 using 2-day PCA treatment. (B) Five-month follow-up, showing similar correction to Exoderm.

response to burning or drainage, beginning immediately after the patient goes home. The ointment is used from day 1 as needed in response to dryness or tightness.

Throughout the week, the patient has to minimize mouth movements in order to avoid cracking the hardened mask. If it does crack, the patient can reapply the powder by slightly wetting it and patting it on. If

a tender skin fissure develops (ie, in the corner of the mouth), the patient can apply Aquaphor Healing Ointment to that area. The patient applies petroleum jelly all over the face on the night of the eighth postoperative day, washes it off in the morning, and then comes into the office.

#### *Postepithelialization Care*

Although almost 100% re-epithelialized by day 8 or 9 (Figure 1D), the skin is still tender. We like to use Aquaphor Healing Ointment after dilute vinegar compresses for the next few days, slowly moving to creams and cleansers (Cetaphil, Galderma Laboratories, Fort Worth, Tex) For sun-block, we prefer products that contain micronized zinc-oxide (MD Forte Aftercare 30; Allergan, Irvine, Calif). We rarely use 1% hydrocortisone but would if very dry areas develop. Make-up can range from the patient's own to camouflage quality lines. As the skin heals, we move away from Aquaphor Healing Ointment to light creams or lotions (within the first 2–3 weeks) in order to avoid milia formation. Should postinflammatory hyperpigmentation develop, we would begin therapy with retinol-containing hydroquinone products. (All phototype III and IV patients develop this routinely, and it is easily reversible.) Figure 1E shows the results at 2 years without any depigmentation or hyperpigmentation.

#### *Touch-Ups*

These are done after 2–3 months to treat individual scars or areas. It is best to repeat the entire 2-day PCA process. No anesthesia is usually required, but field blocks can be used. They re-epithelialize within 5 days. Clinical photographs and evaluation showed either no or barely visible lines of demarcation even in skin type IV.

#### *Paired Comparison Study*

After receiving informed consent, a 17-year-old female patient with acne scars was treated on both cheeks with a regional Stone 2 peel and taped for 24 hours. On the second day, only the right cheek underwent debridement and phenol reapplication. Both cheeks had powder applied for 4–5 days. Photos were taken throughout the healing phase.

#### *Comparative Histologic Study*

In order to compare the wounding properties of Exoderm to Stone 2, with and without the second-day PCA process, a patient with severe acne scars on the back was selected after receiving informed consent. The back was degreased as described above. Sites A

and B were peeled with Stone 2 and taped for 24 hours. Site B was debrided on day 2 and phenol was reapplied. Both sites had powder applied for 4–5 days. Sites C and D were similarly treated with Exoderm, with site D having the second-day PCA.

## **Results**

#### *Cardiac Profiles*

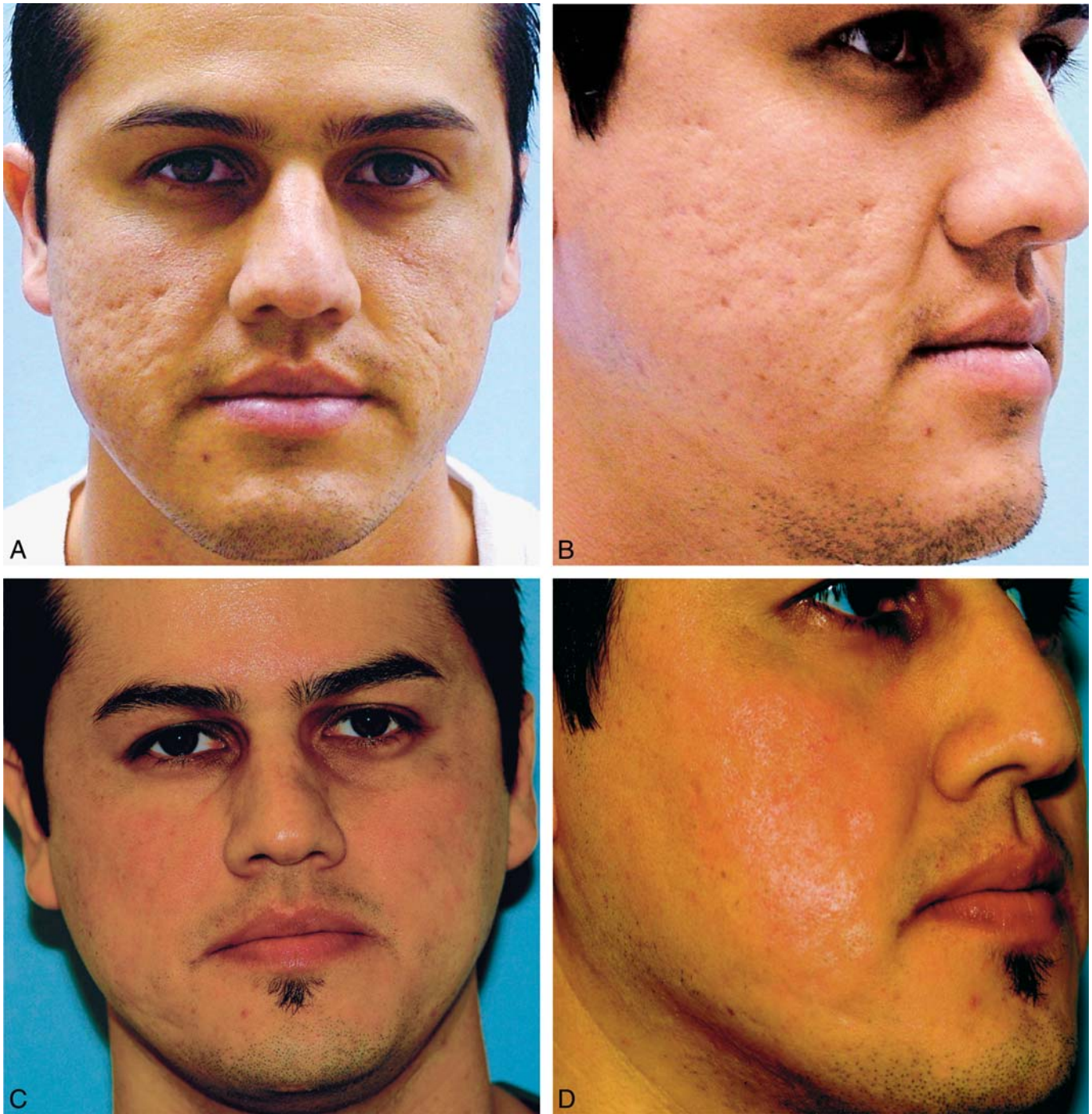
None of the 78 patients revealed problems with arrhythmias once epinephrine in nerve blocks was stopped. The first 30 cases had epinephrine and there was 1 case of asymptomatic PVCs. We had four PAC cases when the acid was being applied over the eyelids. During the last 48 cases, where no epinephrine was used, there were no PVCs or PACs. Heart rate did increase, as did the blood pressure, reflecting the pain during the procedure. Intravenous midazolam and fentanyl were used in dosages and frequencies chosen by the nurse anesthetist. There were no cases of respiratory depression, and there was no need to use narcotic antagonists. The last 5 patients received 0.1 mg of clonidine per os 30 minutes before the procedure, resulting in less tachycardia and blood pressure elevation.

#### *Complications*

There were no infections. There were no cases of facial scarring or depigmentation among the 78 patients. Most phototype III and IV patients had transient hyperpigmentation that resolved with treatment within 2 months. We saw some homogeneous hypopigmentation, mainly in the wrinkled patients, and there was 1 case of facial telangiectasias. Four of the patients who had neck peels developed small scars on their necks, but they all responded completely to intralesional triamcinolone acetonide or pulsed-dye laser treatment. Two of the neck patients had temporary lines of demarcation on the décolleté.

#### *Telephone Satisfaction Survey*

The telephone satisfaction survey reached 41 patients (nearly 60%), and of those with wrinkles, 80% were very satisfied and 20% satisfied; of those with acne scars, 46% were very satisfied and 54% were satisfied. No procedure-induced scars on the face of either the wrinkle or acne scar group were reported. The color of the skin was about the same in 85% of patients with wrinkles, while 10% had a little lighter color; acne scar patients showed 69% were the same and 31% were a little lighter. There was no depigmentation.

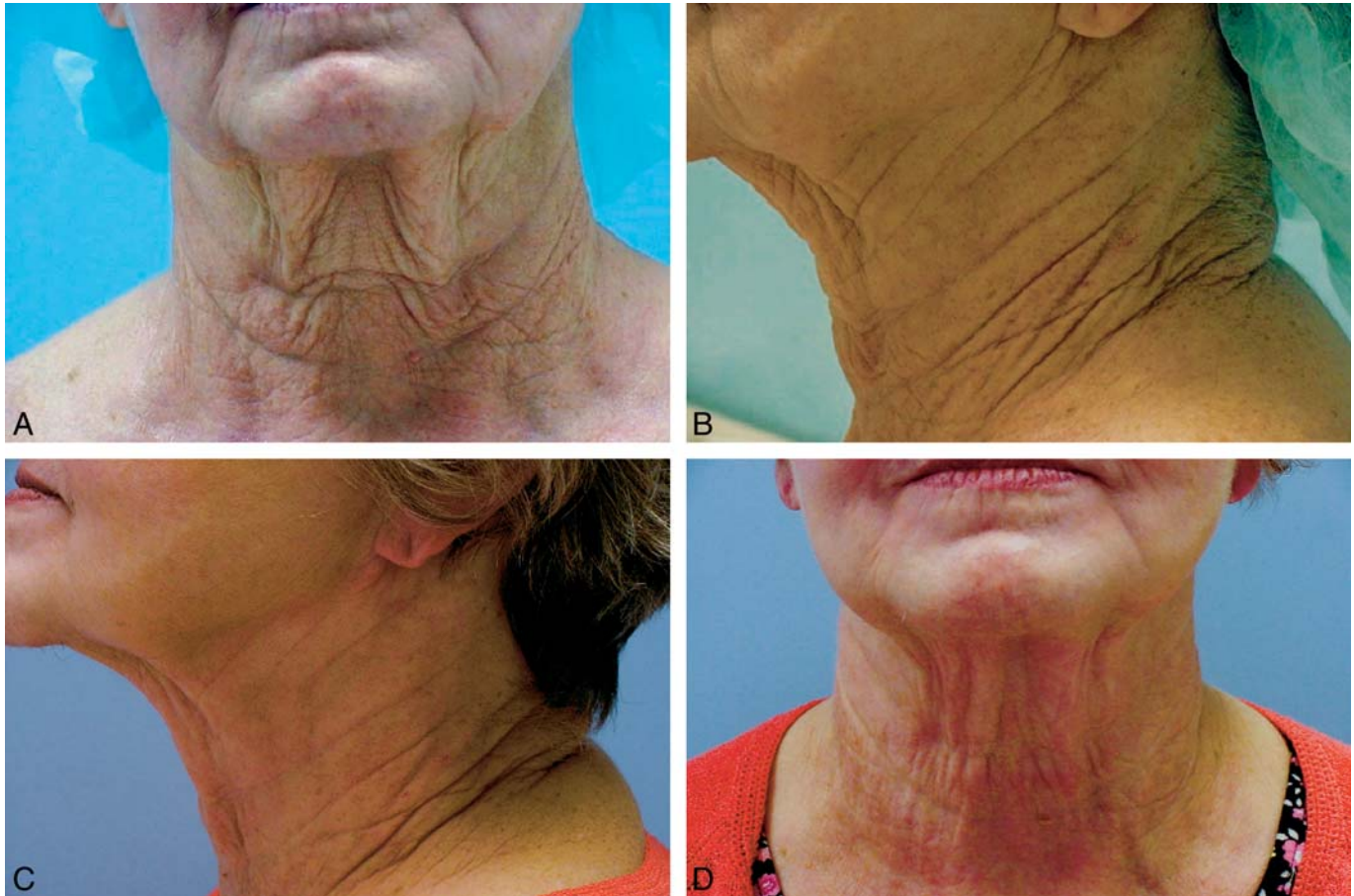

**Figure 4.** (A) Preoperative patient, age 28, SPT-IV, with ice-pick and box acne scars (frontal view). (B) Preoperative patient, lateral view. (C) Twenty-month follow-up, frontal view. Note individual scar remodeling without punch excision. (D) Twenty-month follow-up, lateral view. Note absence of demarcation lines and good face-neck color match.

#### *Photographs*

Four blinded observers assessed the before and after photographs after being shown what a 25, 50, and 100% improvement would look like. Of the 78 cases treated, only 43 had quality before and after photo-

graphs that could allow for objective comparisons. Of these, 30 had been treated for wrinkles, 7 for scars, and 6 for both. Their analysis concluded that patients with acne scars improved 80%, wrinkle patients 90%, and patients with both acne and wrinkles 86%. Serial PCA



**Figure 5.** (A) Preoperative patient, age ??, neck peel, frontal view (using Hetter's neck and eyelid formula). (B) Preoperative patient, lateral view. (C) Patient at 1-month postoperative, frontal view. (D) Patient at 1-month postoperative, lateral view.

(touch-ups) resulted in better results. There were no differences in results noted between those treated with Exoderm and those with Stone solutions (Figures 3A and B and 4A and B). There was clinically apparent tissue contraction noted on the neck (Figure 5A and D).

#### *Paired Comparison*

Our paired comparison study to evaluate the value of doing the 2-day PCA to improve acne scars showed that the PCA-treated side's scars improved significantly more than the side treated only with the taped peel (Figure 6A through D). By day 5, the scars on the 2-day PCA-treated side looked deeper, but they began filling in by the eighth day, and by day 30, had filled in much more than the side that only had the peel.

#### *Histology*

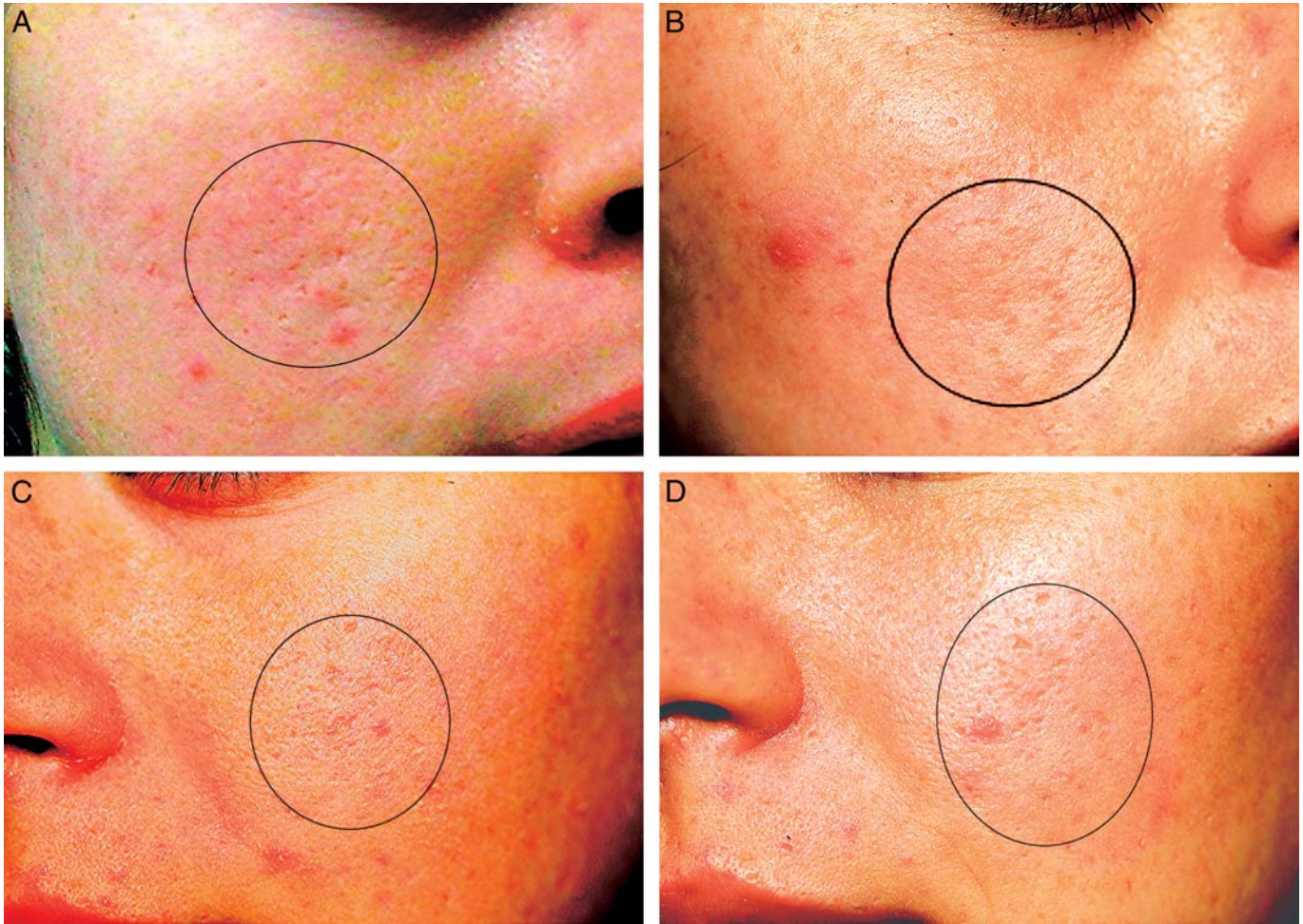The skin biopsy study to evaluate the wounding properties of Stone 2 and Exoderm showed that all 4 sites (A was 0.5 mm and B–D were 0.4 mm on day 9)

had almost equal depth of penetration of injury through the papillary dermis into the superficial reticular dermis. The inflammatory cell infiltrate went down to a depth of 1.9 mm in site A and 1.3 mm in site C. These were deeper than the PCA sites B and D, which went down to 0.7 mm. This result showed that the second-day reapplication of phenol did not cause a deeper tissue injury.

#### **Discussion**

These results confirm prior studies on light modified phenol<sup>(3–8,11,12)</sup> that portray these peels as both effective and without the classic complications that have been associated with Baker-Gordon phenol peels. This is the first study, to the authors' knowledge, that compares Exoderm-Lift to Stone 2 in clinical efficacy and histologic wounding properties. It is also the first study that evaluated the role of the second-day PCA versus the peel alone in the treatment of acne scars. This study strongly supports the value of the second-day





**Figure 6.** (A) Treated with 2-day PCA with visible improvement. (B) One month after 2-day PCA treatment. (C) Treated only with 24 hour taped phenol with no improvement. (D) One month after 24-hour taped phenol treatment.

debridement and phenol reapplication in the treatment of both scars and deep wrinkles. It argues for the possibility that the 2-day PCA can become the treatment of choice for resurfacing deep scars and wrinkles. The ready availability of a commercially premixed, stable phenol formula (Exoderm and Stone formulations), allows cosmetic surgeons to finally have a phenol peel that can be studied, taught, and used in many clinical applications.

Hetter<sup>3-6</sup> and Stone<sup>7,8</sup> (both plastic surgeons) independently helped clarify phenol dogmas that had been accepted for 35 years. They concluded that phenol is not the only active ingredient in all published formulas. They feel that croton oil, as a vesicant, dilutes the phenol slightly, but more importantly acts to increase phenol's penetration. Therefore, the higher the croton oil concentration, the more the phenol penetrates. Formulas with less than 1% croton oil will

not cause abnormal pigment loss or healing delays.<sup>3-6</sup> Cardiac toxicity can be avoided with slow application, avoiding epinephrine, and with low croton oil concentrations.<sup>7,8</sup> Technique is as important as formula. Hetter describes his technique of light phenol neck peels.<sup>6</sup>

Credit is owed to Fintsi<sup>11</sup> for his innovative work on Exoderm chemabrasion published in 1997. He developed this technique for the treatment of acne scars and felt that "secret ingredients" in his buffered formula were the reason why he could safely reapply phenol on abraded skin on the second day and that it would not penetrate beyond a certain depth. Stone disagrees (written communication, March 2004), stating that it is the technique and percent of croton oil that are the key safety factors allowing phenol to be reapplied on a second day. Our histologic study seems to confirm Stone's argument. In it, both Stone 2 and

Exoderm showed (a) virtually equal wounding properties; (b) that the second-day debridement may reduce the inflammatory response to injury by removing necrotic epidermis; and (c) the second-day application of phenol on abraded skin did not increase its depth of injury.

Dr Edward Becker (Walnut Creek, Calif) should be recognized for bringing the Fintsi technique to the United States. Until recently, he was the US distributor and helped train dozens of physicians on the Exoderm-Lift technique.

This study analyzed cardiac and cutaneous side effects from the 2-day PCA peel, and our results confirmed prior reports. A review of Fintsi's publication,<sup>12</sup> where he reports on 3000 cases, Becker's 4-year experience on 100 cases (oral communication, March 2004), and Stone's 12 years of experience with modified phenol peels (oral communication, March 2004) show that their patients experienced no significant arrhythmias other than a very low incidence of sinus tachycardia (approximately 6%) and very rare, asymptomatic PVCs (usually epinephrine related). All of these physicians applied their phenol peels over a 1-hour period. No evidence has been presented in any of these studies to explain whether it is the safety of these modified formulas or the slow pace of application that prevents the cardiac arrhythmias associated with phenol peels. Future studies that evaluate the application of modified peels over a 30–45-minute period could clarify this question.

Our study confirms the absence of serious cutaneous side-effects, as reported by Fintsi, Becker, and Stone. Their patients experienced no facial scars or depigmentation, but did report some homogeneous hypopigmentation, especially after 2 years (more closely matching the color on the inside of one's sun-shaded forearm). Our most troubling cutaneous side effects were on the neck, where we experienced some minor scars and temporary hypopigmentation, which created lines of demarcation due to the solar dyschromia in untreated chests.

There was an incident in New Zealand where a patient died while undergoing an Exoderm peel, but the investigation concluded that it was due to doctor error from overmedication with IV anesthetics without any monitoring or resuscitative equipment available (Edward Becker, personal communication, March 2004). There was a recent case of an adverse result from Exoderm peel in the United States that could possibly be related to use of solutions from outside the United States (Edward Becker, personal communica-

tion, March 2004). Because the Stone solutions are made and sold commercially through a compounding company, we feel a higher trust and comfort level using them instead of using an unknown formula made in a foreign country by the proprietary company.

Of the 78 cases treated with modified phenol formulas, 8 were treated with the open 1-day technique, with a postoperative regimen of vinegar compresses and Aquaphor. That technique was discontinued after seeing better results with the 2-day PCA. We saw more consistent and predictable healing stages and less erythema by days 9 and 10. We feel that the application of the bismuth subgallate powder is responsible for that consistency. Deeper perioral wrinkles also improved more with the 2-day, taped PCA technique.

The ability of phenol to clinically liquefy the epidermis and upper dermis is unique when compared with other resurfacing modalities. This allows for easy and controlled abrasion of not only scarred or wrinkled areas but also individual deep ridges and pits. The reapplication of phenol on abraded skin, although an alarming concept, turned out to be not only safe but necessary to achieve a more significant remodeling of the deep edges of these scars and wrinkles. Of interest is that the first study on using phenol for acne scars was published in the 1952 by Mackee,<sup>12</sup> who noted his experience using serial liquefied phenol peels beginning in the very early 1900s.

Kadunc and de Almeida<sup>13</sup> recently published an excellent report categorizing acne scars so that we could better analyze and compare treatment modalities according to types of scars. Our 2-day PCA peel could be added to the current armamentarium that they describe. Lee<sup>14</sup> published his work on the CROSS (chemical reconstruction of acne scars) technique where, 100% TCA is applied with sharp-tipped Q-tips into acne scars, in a way reminiscent of the way we use phenol on both days. He also recommends the serial approach that we followed with our touch-ups. He recognizes the scarring potential of TCA on adjacent skin, a danger we did not see with light phenols. Batra<sup>15</sup> recently published a study that surveyed patients who had been resurfaced with carbon dioxide or erbium: YAG laser as long as 2½ years earlier. In it, 42% of patients commented on insufficient results in areas of dynamic rhytids, especially in the perioral region. Clearly, laser surgeons should reassess other treatment options (like the 2-day PCA) for these areas.

Chemical or laser peels in combination with abrasion have been studied for years. Stagnone<sup>16</sup> used TCA and dermabrasion in his study published in 1977. Fulton<sup>9</sup>

feels that deep acne scars are best treated by combining CO<sub>2</sub> laser with dermabrasion.

Phenol neck peels are also a controversial subject. The technique most widely accepted for the neck is using Jessner's<sup>18</sup> or glycolic<sup>19</sup> acid solution in combination with 20–35% TCA. A paired comparison study is needed to examine whether these peels or our light phenol peels will not only work better but have a lower incidence of side effects. Our patients' skin color and texture definitely improved with our peels on the neck, which allowed for a better blending with the face. There was a low but significant incidence of scarring and temporary hypopigmentation, but these all resolved with standard treatments. Uneven application resulting in areas having deeper penetration of the phenol probably explains these scars. Another problem is how to peel necks and chests that are very freckled, and deciding how far down the décolleté to apply the peel. There was an impressive initial tightening of the neck and jowls, and 20–25% of that seems to remain for 2 years. Both the Hetter neck and eyelid formula and the Stone formulations seemed to work equally as well, but a paired comparison is also indicated.

As to why the benefits of phenol peels seem to last longer than carbon dioxide laser, reference is made to Moy and Kotler's<sup>19</sup> article, where they performed a histologic evaluation of one versus the other. Their conclusion was that phenol peels resulted in the formation of a thicker zone of collagen despite the deeper ablation depth of the laser. Paired comparison of the histologic wounds (on facial skin) of both ablative lasers and the PCA peel is also indicated.

### Conclusion

Modified light phenol peels are safe and effective. Our study confirms prior reports. The 2-day PCA is a reproducible deep chemical peel with consistent and predictable healing stages. It can be taught as a well-defined procedure. Training and experience are absolutely required. The Stone formulas are clinically equally as effective as Exoderm. They cost much less, are made by a US-based and very reliable company, and their composition is not secret. Buying commercially available formulas avoids the variability of mixing one's own. Regional touch-ups with the 2-day PCA are more effective than single treatment, especially for acne scars and deep, dynamic perioral wrinkles. Neck and chest peels have more complications but merit further study. They help blend the face with the neck in color and texture and produce a reasonable cosmetic improvement.

We would like to acknowledge John Campbell, MD (San Diego), and the Staff at the Dermatology Institute, Chula Vista, Calif.

### References

1. Baker TJ. Chemical face peeling and rhytidectomy: a combined approach for facial rejuvenation. *Plast Reconstr Surg.* 1962;29:199.
2. Litton C. Chemical face lifting. *Plast Reconstr Surg.* 1962;29:371.
3. Hetter G. Examination of the phenol-croton oil peel: part I. Dissecting the formula. *Plast Reconstr Surg.* 2001;105:227–239.
4. Hetter G. Examination of the phenol-croton oil peel: part II. The lay peelers and their formulas. *Plast Reconstr Surg.* 2001;105:240–248.
5. Hetter G. Examination of the phenol-croton oil peel: part III. The plastic surgeons' role. *Plast Reconstr Surg.* 2001;105:752–763.
6. Hetter G. Examination of the phenol-croton oil peel: part IV. Face peel results with different concentrations of phenol and croton oil. *Plast Reconstr Surg.* 2001;105:1061–1083.
7. Stone P. Modified phenol peels—role of the application technique. *Clin Plast Surg.* 1998;25:21–44.
8. Aronsson A, Erikssohn T, Jacobsson S, et al. Effects of dermabrasion on acne scarring: a review and a study of 25 cases. *Acta Derm Venereol.* 1997;77:39–42.
9. Fulton J. Dermabrasion, chemabrasion and laser abrasion. *Dermatol Surg.* 1996;22:619–628.
10. Fintsi Y. Exoderm chemoabrasion for acne scars. *Int J Cosmet Surg.* 1998–9;6:111–114.
11. Fintsi Y. Exoderm—a novel, phenol-based peeling method resulting in improved safety. *Am J Cosmet Surg.* 1997;14:45–56.
12. Mackee GM, Karp FL. The treatment of post-acne scars with phenol. *Br J Dermatol.* 1952;64:456–459.
13. Kadung VB, DeAlmeida RT. Surgical treatment of facial acne scars based on morphologic classification: a Brazilian experience. *Dermatol Surg.* 2003;29:1200–1209.
14. Lee BL, Chung WG, Kwahck H, Lee KH. Focal treatment of acne scars with chemical reconstruction of skin scars method (CROSS). *Dermatol Surg.* 2002;28:1017–1021.
15. Batra RS, Jacob CI, Hobbs L, Arndt KA, Dover JS. A prospective survey of patient experiences after laser skin resurfacing. *Arch Dermatol.* 2003;139:1295–1299.

16. Stagnone JJ. Chemabrasion, a combined technique of chemical peeling and dermabrasion. *J Dermatol Surg Oncol.* 1977;3:217–219.

17. Monheit GD. The Jessner's + TCA peel: a medium-depth chemical peel. *J Dermatol Surg Oncol.* 1989;15:945–950.

18. Coleman WP, Futrell JM. The glycolic acid + trichloroacetic acid chemical peel. *J Dermatol Surg Oncol.* 1994;20:76–80.

19. Moy LS, Kotler R. The histologic evaluation of pulsed carbon dioxide laser versus phenol chemical peels in vivo. *Dermatol Surg.* 1999;25:597–600.